Automated Identification of Neoplasia in Diagnostic Imaging text reports

"This work has been funded in whole or in part with Federal funds from the National Cancer Institute, National Institutes of Health, Department of Health and Human Services, under Contract No. HHSN261200900040C“

George Cernile
Artificial Intelligence in Medicine, Inc.
Suzanne March
QuantumMark LLC.

Objective

- To extend the use of natural language programming techniques to other sources of data beyond pathology reports.

Introduction

The Team

- QuantumMark – PI & Project Management
- AIM - Knowledge Engineering & Development
- April Fritz & Associates – Domain Expertise, Cancer Registrar

Participating Institutions

- 12 data providers including registries, labs and hospitals

Radiology Reports

HMR 0013 - MRI BRAIN W/WO CONTRAST - Aug 1 2007

FINDINGS: MRI of the brain with contrast.

Clinical Indication: 82-year-old female with **history of meningioma**.

Technique: MRI of the brain was obtained using the following sequences:sagittal T1, axial T1, axial FLAIR, axial T2, axial diffusion, axial ADC, axial postcontrast T1, and coronal postcontrast T1 weighted sequences.

Comparison: comparison is made to an MRI of the brain from an outside institution (Downey Regional Med Ctr) dated 12/5/2006.

There are no extra-axial fluid collections. A right frontal extra-axial parasagittal mass demonstrating isointense T1 signal to gray matter and intermediate to high signal intensity on T2 images with marked homogeneous enhancement postcontrast is noted to measure 2.6 cm transverse x 3.4 cm AP x 3.5 cm craniocaudal. Marrow signal changes in the calvarium abutting the mass are suspicious for interosseous involvement. When compared to the prior study of 12/5/2006, the size and appearance of the mass demonstrates no significant change. There is a minimal to mild mass effect on the adjacent right frontal lobe without evidence of edema.

The ventricles and cortical sulci are prominent consistent with mild to moderate cerebral atrophy. There is no hydrocephalus. The supratentorial brain parenchyma demonstrates scattered foci of T2 and FLAIR hyperintensities noted throughout the periventricular, subcortical, and deep white matter of both cerebral hemispheres, which are nonspecific, and likely represents chronic ischemic changes. The bilateral basal ganglia demonstrate T2 and FLAIR hypointensity.

The cerebellum demonstrates mild atrophy. The brainstem appears normal. There are no parenchymal masses or midline shift.

The are no restricted diffusion abnormalities.

Mild right anterior ethmoid sinus mucosal disease is noted. A minimal amount of fluid is noted in the right mastoid air cells. The orbits, remaining paranasal sinuses, and calvarium are unremarkable.

IMPRESSION:

1. Right frontal parasagittal **meningioma**, relatively unchanged in size and appearance when compared to the prior outside study dated 12/5/2006, including marrow signal changes in the calvarium adjacent to the lesion suggestive of intraosseous involvement.
2. Nonspecific white matter disease as described above, likely reflecting chronic ischemic changes.
3. Mild right anterior ethmoid sinus mucosal disease. Minimal amount of fluid noted in the right mastoid air cells..

Imaging terms – 1st pass

Term	Select	Term	Select
hyperintensity FLAIR		white matter change	
hyperintensity T2-weighted		STIR hyperintensity	
T2 hyperintensity		leukomalacic changes	
abnormal density white matter	Yes	choroid plexus cyst	
mass effect	Maybe	demyelinating disease.	
abnormal enhancement	Maybe	brain tumor	Yes
high density lesions		heterogeneous enhancement	Yes
low density lesions	Yes	infarction / infarct	
abnormalities	Maybe	white matter signal abnormality	
abnormal enhancement		chiari malformation	
small vessel disease		chronic ischemic change	
extraaxial mass lesions	Yes	low attenuation changes	Maybe
increased signal intensity	Maybe	Edema / Oedema	
abnormal signal intensity	Yes	vasogenic Edema/Eodema	Yes
enhancement	Yes	BBB (Blood Brain Barrier)	Yes
pathologic mass	Yes	Infiltrative lesion	Yes
increased density	Yes	tumor	Maybe
retention cyst.			

Selection Rate > 30%

Imaging terms – 2nd pass

Term	Select	Term	Select
hyperintensity FLAIR		white matter change	
hyperintensity T2-weighted		STIR hyperintensity	
T2 hyperintensity		leukomalacic changes	
abnormal density white matter		choroid plexus cyst	
mass effect	Maybe	demyelinating disease.	
abnormal enhancement		brain tumor	Yes
high density lesions		heterogeneous enhancement	
low density lesions		infarction / infarct	
abnormalities		white matter signal abnormality	
abnormal enhancement		chiari malformation	
small vessel disease		chronic ischemic change	
extraaxial mass lesions	Yes	low attenuation changes	
increased signal intensity		Edema / Oedema	
abnormal signal intensity		vasogenci Edema/Eodema	
enhancement		BBB (Blood Brain Barrier)	
pathologic mass	Yes	Infiltrative lesion	Yes
increased density		tumor	Maybe
retention cyst.			

Selection Rate ~ 10%

Process Clinical Indication Section

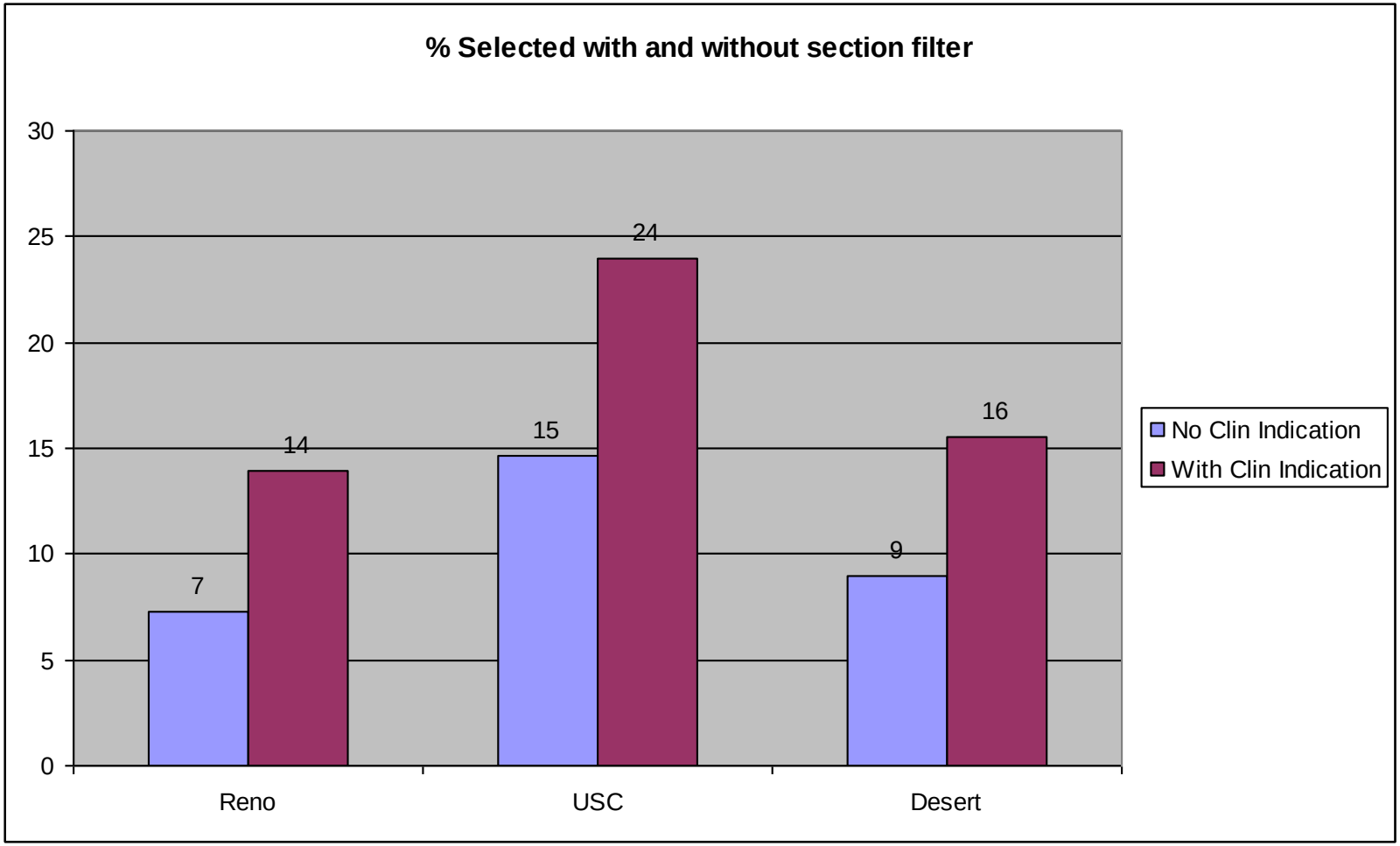

Phase I Results

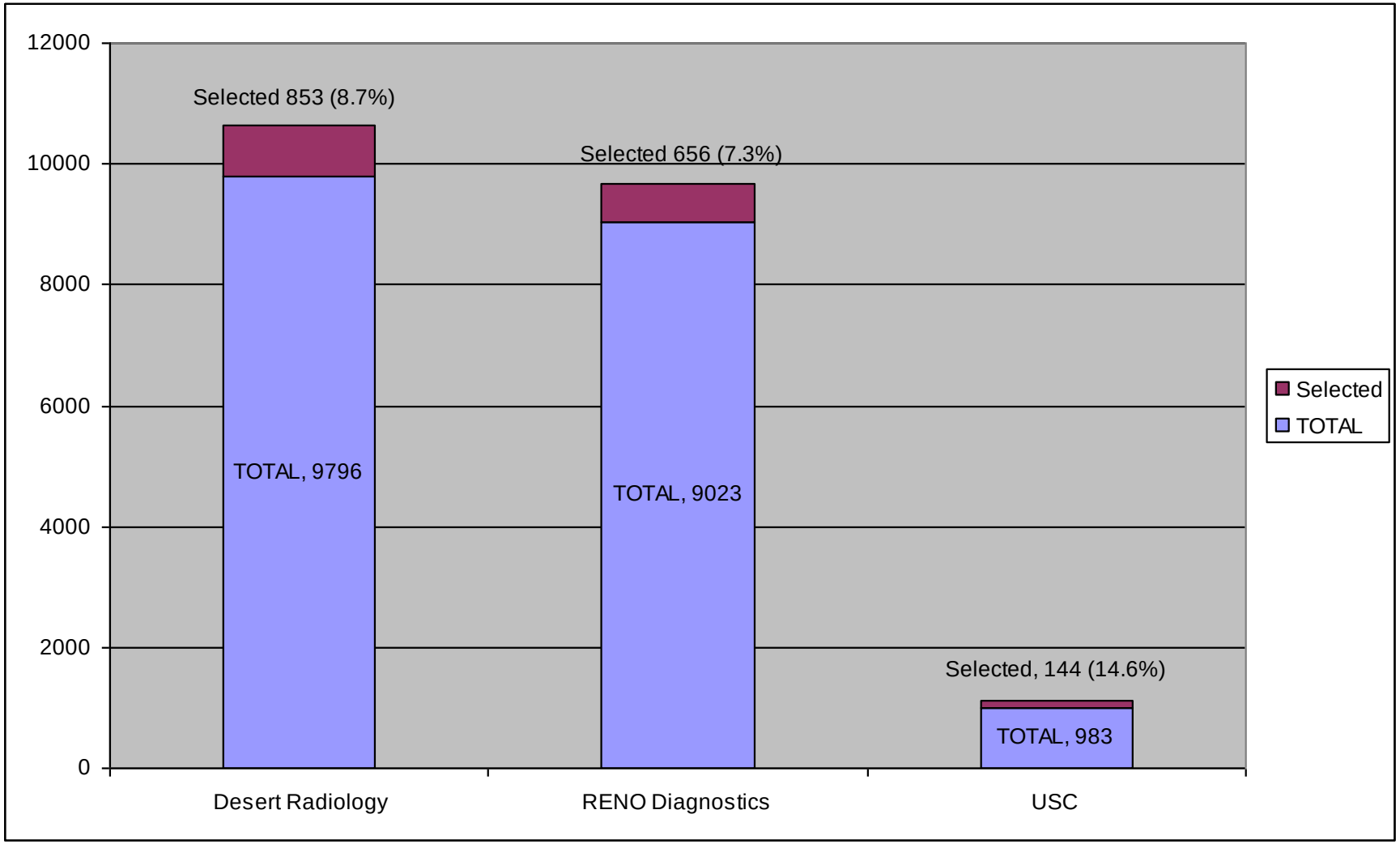

Phase II

- Installed into 3 registries and an initial run was done to determine performance and receive feedback.

Different requirements

- One registry was very sensitive to false positives, and in fact wanted only tumors that were new to the registry.

- Another registry wanted all cancers for follow-up with existing registry data.

Two different case-findings

1. Identify reports of the diagnosis, differential diagnosis, metastasis or history of primary CNS neoplasms or non CNS neoplasms of behavior greater than 2.

2. Identification of a diagnosis or differential diagnosis of a primary CNS neoplasm.

Sensitivity and Specificity Results for QC Study 1289 Reports

Bundle	True Positive	True Negative	False Positive	False Negative	Sensitivity	Specificity
B0096	4	90	2	0	100%	97.8%
B0097	16	81	3	0	100%	96.4%
B0098	13	78	4	0	100%	95.1%
B0103	5	93	1	1	83.3%	98.9%
B0108	15	83	2	0	100%	97.6%
B0110	10	88	2	0	100%	97.8%
B0111	1	92	6	0	100%	93.9%
B0112	10	87	2	0	100%	97.8%
B0113	7	90	3	0	100%	96.8%
B0115	15	78	7	0	100%	91.8%
B0116	13	86	1	0	100%	98.9%
B0117	10	86	4	0	100%	95.6%
B0118	5	91	3	1	83.3%	96.8%
Total	124	1123	40	2	98.4%	96.6%

Extended Classifications

- Negative
- History of cancer
- Metastatic tumor
- Positive previously known
- Positive

- This information would allow increased decision making as well as provide information to registries.

Report classification

	Classification	History of Tumor	Metastatic Tumor	CNS Tumor	Non CNS Tumor
1	Negative	-	-	-	-
2	History	yes	-	-	yes
3	Metastatic	implied	Yes	implied	implied
4	Positive previously known	yes	-	yes	-
5	Positive	-	-	yes	-

What about Sensitivity and Specificity?

	Classification	History of Tumor	Metastatic Tumor	CNS Tumor	Non CNS Tumor
1	Negative	-	-	-	-
2	History	yes	-	-	yes
3	Metastatic	implied	Yes	implied	implied
4	Positive previously known	yes	-	yes	-
5	Positive	-	-	yes	-

What about Sensitivity and Specificity?

	Classification	History of Tumor	Metastatic Tumor	CNS Tumor	Non CNS Tumor
1	Negative	-	-	-	-
2	History	yes	-	-	yes
3	Metastatic	implied	Yes	implied	implied
4	Positive previously known	yes	-	yes	-
5	Positive	-	-	yes	-

What about Sensitivity and Specificity?

	Classification	History of Tumor	Metastatic Tumor	CNS Tumor	Non CNS Tumor
1	Negative	-	-	-	-
2	History	yes	-	-	yes
3	Metastatic	implied	Yes	implied	implied
4	Positive previously known	yes	-	yes	-
5	Positive	-	-	yes	-

What about Sensitivity and Specificity?

	Classification	History of Tumor	Metastatic Tumor	CNS Tumor	Non CNS Tumor
1	Negative	-	-	-	-
2	History	yes	-	-	yes
3	Metastatic	implied	Yes	implied	implied
4	Positive previously known	yes	-	yes	-
5	Positive	-	-	yes	-

Positive – Previously Known

Report Classifier - All Classifications.csv

File Edit Tools

Aut CF		Code	Description
3	-	AIM-930-...	recurrence
4	+	C09.9	Tonsillar
2	+	C41.2	Spine
1	+	C53.9	Cervical
	+	C71.0	Cerebral [JC - RAD]
	+	C71.3	Parietal lobe
	+	C71.5	Lateral ventricle, NOS
	+	C71.5	Ventricle, NOS
	+	C71.7	Fourth ventricle, NOS
	+	C71.8	Corpus callosum
	+	C71.9	Brain, NOS
	+	C76.0	Head
	+	COVER	MRI brain [AJ - RAD]
	+	HX	History
	-	M-80001	Mass, NOS [JC - RAD]
	+	M-80001	Tumor NOS
	+	M-94703	Medulloblastoma, NOS (...

Case Finding

- Positive
- Positive - Previously Known
- History
- Metastatic
- Negative
- Flag report

Comment

Manual: Positive (Previous

[GROSS PATHOLOGY]

Note is made of a right parietal approach ventricular shunt catheter with the catheter passing through the right lateral ventricle from a posterior to anterior direction, the tip terminating in the region of the anterior aspect of the corpus callosum. There has been interval ventricular dilatation. The ventricles were mildly dilated on the prior study and are currently of normal caliber with the exception of postsurgical widening of the fourth ventricle.
Within the supratentorial space, there has been the interval decrease in degree of edema within the subcortical white matter in the right parietal lobe in the inferior parietal lobule at the site of ventricular shunt placement. There is no evidence of acute cerebral infarction. In this patient with right-sided weakness, there is no evidence of left-sided white matter edema or cortical infarction in the supratentorial space. There is no midline shift.
Within the infratentorial space, note is made of postsurgical change following suboccipital craniectomy for resection of a **medulloblastoma.** They are secondary postoperative widening of the fourth ventricle. There is no evidence of a brainstem infarction. There is cerebellar tonsillar ectopia with secondary narrowing of the CSF spaces of the foramen magnum.

[CLINICAL HISTORY]

UNSPEC SURGERY FOLLOW
ADMIT DATE/TIME:
Brain tumor removed in April 2
MRI of brain performed May 7, 2010. CT head performed April 27, 2010.

Resection medulloblastoma
Post surgical change

[FINAL DIAGNOSIS]

1. Interval resolution of pneumocephalus following surgery with interval ventricular decompression following placement of a ventricular shunt catheter. The ventricles are now of normal caliber.
2. Postoperative change following resection of a **medulloblastoma** at the level the fourth ventricle.
3. Soft tissue at the foramen magnum compatible with moderate cerebellar tonsillar ectopia. Given the patient's new onset right-sided weakness and absence of CT evidence of infarction, recurrent or residual mass or progressive hemorrhage in the brain, further evaluation with an MRI of the cervical spine to evaluate for the degree of cerebellar tonsillar ectopia and for the possibility of cervical syrinx or compression of the cervicomedullary junction may be of benefit.
Dictated by: Robert J Kadner, M.D.
Images and Report reviewed and interpreted by: Robert J Kadner, M.D.
<PS><Electronically signed by: Robert J Kadner, M.D.>
05/25/2010 1252

Positive

Report Classifier - All Classifications.csv

File Edit Tools

Aut CF	Code	Description
3	+ C69.6	Orbit, NOS
4	+ C71.1	Left frontal (Heuristic,...
2	+ C71.1	Frontal lobe
1	+ C71.5	Ventricle, NOS
	+ C71.9	Craniotomy (Heuristic,...
	+ C71.9	Brain, NOS
	+ C72.3	Optic chiasm
	+ C75.1	Pituitary gland
	+ C75.1	Pituitary, NOS
	+ C76.0	Head
	+ COVER	MRI brain [AJ - RAD]
	+ HX	History
	- M-80001	Enhancing mass [AJ -...
	+ M-81400	Microadenoma [JC - ...
	- M-82720	Pituitary adenoma, N...

Case Finding
- (•) Positive
- ( ) Positive - Previously Known
- ( ) History ( ) Metastatic
- ( ) Negative [ ] Flag report

Manual: **Auto:** Positive

Comment

MR BRAIN WITHOUT AND WITH CONTRAST

TECHNIQUE: Coronal T2, sagittal T1, post gadolinium dynamic coronal T1, and post gadolinium sagittal T1 weighted images of the pituitary; coronal FLAIR, axial T2, and post gadolinium axial T1 weighted images of the head; 20 mL intravenous Omniscan given.

[GROSS PATHOLOGY]

FINDINGS: Pituitary gland is bulbous in appearance. It measures 10 x 14 x 9 mm in maximal AP, transverse, and craniocaudal dimensions. In the right side of the gland, there is a 4 mm round hypoenhancing lesion. It is not well visualized on the T1 and T2 weighted images. Infundibulum is midline. Optic chiasm is normal in appearance. There is no enhancing intracranial mass. A developmental venous anomaly is in the posterior left frontal lobe. No definite intracranial hemorrhage. Ventricles differentiation is intact. patent. Orbits are intact inferior left maxillary sin

Pituitary gland microadenoma and no other neoplasm

[CLINICAL HISTORY]

eval for pituitary adenoma.

HISTORY: Increased serum prolactin level. Female problems.

[FINAL DIAGNOSIS]

IMPRESSION:
Pituitary gland **microadenoma**.
Job: 486414

History of cancer

Report Classifier - All Classifications.csv

File Edit Tools

Auto CF	Code	Description
3	- AIM-930-...	mass effect
4	+ C30.1	Middle ear
2	+ C49.9	Vessel, NOS
1	+ C61.9	Prostate, NOS
	+ C71.0	Cerebral [JC - RAD]
	+ C71.5	Ventricle, NOS
	+ C71.9	Brain, NOS
	+ C76.0	Head
	+ C80.9	Fluid
	- COVER	Mass effect [JC - RAD]
	+ COVER	MRI brain [AJ - RAD]
	+ HX	History
	+ M-80003	Cancer

Case Finding

- Positive
- Positive - Previously Known
- History
- Metastatic
- Negative
- Flag report

Manual: **Auto:** History

Comment

[NATURE OF SPECIMEN]

TECHNIQUE- Axial T1, FLAIR, fat-suppressed T2, axial diffusion, sagittal T1 and postcontrast axial fat-suppressed T1 and coronal and sagittal T1-weighted images were obtained of the entire head.

[GROSS PATHOLOGY]

FINDINGS- There is some minimal T2 high signal in the periventricular white matter compatible with minimal small vessel disease. The remainder of the brain parenchyma is normal in signal intensity. The ventricles are normal in size. There is no localized mass effect. There is no midline shift. No extraaxial fluid collections are identified. No abnormal areas of enhanc
sinuses, mastoid air cells,
voids are demonstrated wi
sinuses.

History of prostate cancer
No other neoplasm

[CLINICAL HISTORY]

CLINICAL HISTORY- Vertigo for a year. Patient has a history of prostate **cancer**.

[FINAL DIAGNOSIS]

IMPRESSION- Normal MRI of the head. The etiology of the vertigo for a year is not established on this exam. Please correlate clinically.

Metastatic

Report Classifier - All Classifications.csv

File Edit Tools

Auto CF	Code	Description
3	+ C64.9	Renal, NOS
4	+ C71.0	Central white matter
2	+ C71.1	Frontal lobe
1	+ C71.1	Left frontal (Heuristic, JC ...
	+ C71.4	Occipital pole
	+ C71.9	Brain, NOS
	+ COVER	MRI brain [AJ - RAD]
	+ HX	History
	+ M-80001	Tumor NOS
	+ M-80001	Enhancing lesion (AJ - R...
	+ M-80003	Cancer
	- M-80006	Metastatic
	+ M-80006	Metastatic

Case Finding
- Positive
- Positive - Previously Known
- History (•) Metastatic
- Negative [ ] Flag report

Manual: **Auto:** Metastatic

Comment

[GROSS PATHOLOGY]

FINDINGS- The diffusion sequence demonstrates an area of signal loss centrally within a metastatic deposit involving the white matter of the left frontal lobe centrally. This was present previously. A peripheral zone of vasogenic edema is noted which measures 6.2 cm in AP dimension. On the prior examination this measured 5.1 cm. A irregular and somewhat ring-**enhancing lesion** is present in the left frontal lobe. This measures 2.7 x 2.2 x 2.5 cm in craniocaudal, AP and transverse dimensions respectively. On the prior examination same **enhancing lesion** measured 1.8 x 1.8 x 1.9 cm in the same planes. The prior examination also demonstrated a 3 mm nodular lesion involving the left occipital pole with an area of vasogenic edema measuring approximately 2.2 x 1.0 cm in size. On the current e
size and the area of v
in size. Note is made
intensity on the T1 pr
edema. This may rep
hemorrhage. Further
CT examination of the

History of renal cancer with lesions on frontal lobe

[CLINICAL HISTORY]

CLINICAL HISTORY- 55-year-old with a history of renal cell cancer, metastases, follow up.

[FINAL DIAGNOSIS]

IMPRESSION- Enlargement of a left frontal lesion with associated increasing vasogenic edema. There is also enlargement of a left occipital metastatic deposit with increase in vasogenic edema as well. Areas of increased signal intensity on the precontrast sequence along the margins of the occipital edema may represent elements of petechial hemorrhage. The above information was called to and discussed with Dr. Kommor at the time of the dictation.

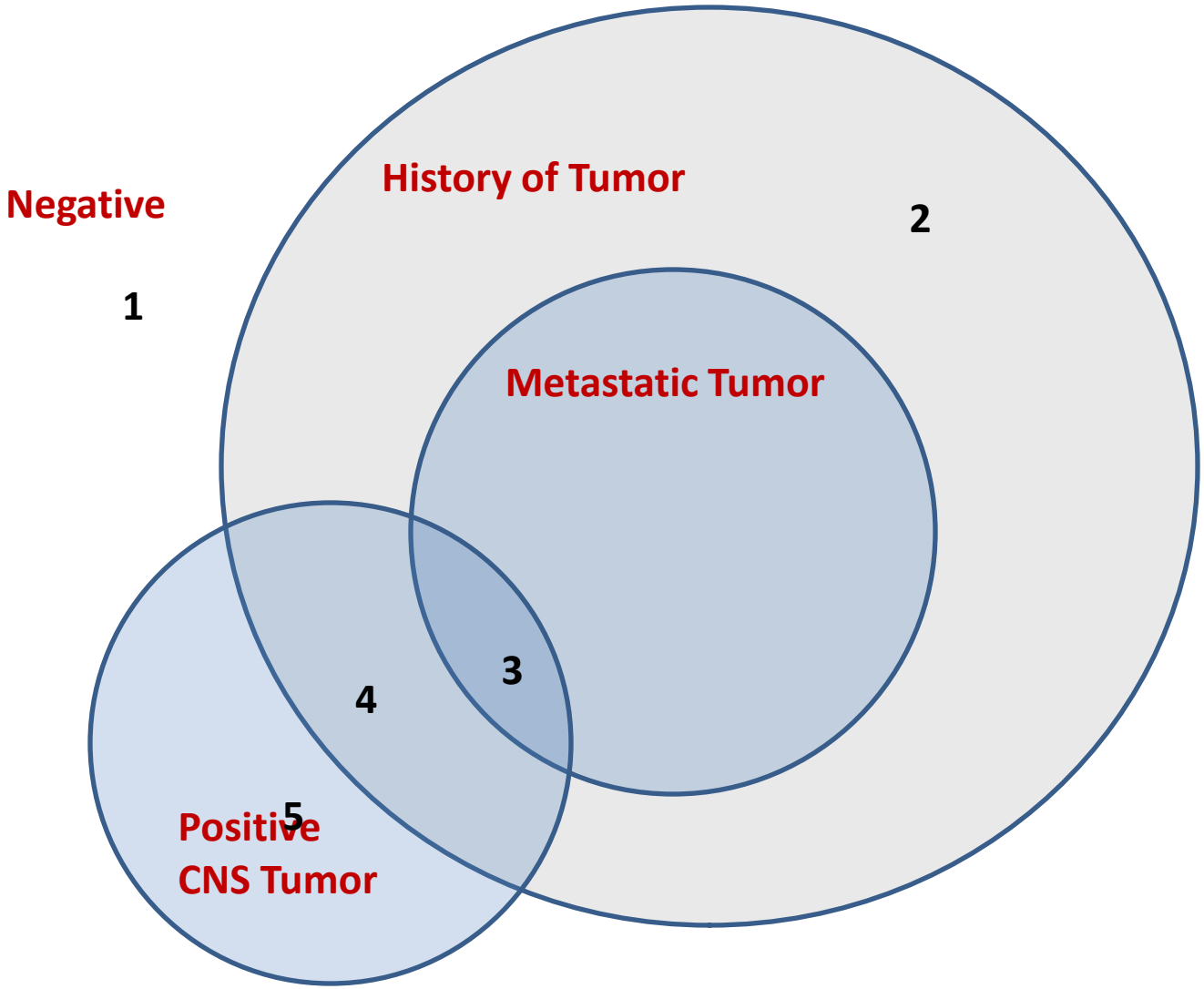
Negative
1
History of Tumor
2
Metastatic Tumor
3
4
5
Positive
CNS Tumor

Results

Bundle	True Positive	True Negative	False Positive	False Negative	Sensitivity	Specificity
B0076	12	82	5	1	.923	.942
B0077	13	83	2	1	.929	.976
B1011	113	78	9	0	1	.897
B1012	78	22	0	0	1	1
…						
B1022	84	8	6	2	.977	.571
B1023	86	8	6	0	1	.571
Total Normal distribution	280	1134	67	15	.949	.944
Total Positive enriched	1981	202	94	25	.988	.682
Total Combined	2261	1336	161	40	.982	.892

Problem

Report Classifier - B1016 HCA v1 lkc-Amin.csv

File Edit Tools

Report	Auto CF	CF
2387253	3	3
2387355	2	2
2387508	1	1
2388082	2	1
2388090	0	3
2388123	2	2
2388228	0	2
2388795	2	1
2388945	2	2
2389377	1	3
2389465	2	2
2389487	1	1
2389712	2	2
2390254	1	2
2390511	2	2
2389320	2	2
2390613	3	0
2390780	1	1
2390838	2	2
2390880	3	0
2391443	2	2
2391472	1	1
2391545	1	1
2391675	1	1
2391776	2	2
2391784	2	3
2391840	3	3
2391996	1	2
2392028	2	1
2392069	2	2
2392258	2	2
2391036	3	3
2391101	2	2
2393031	1	1

	Code	Description
+	C30.1	Middle ear
+	C41.0	Skull, NOS
+	C41.0	Calvarium
+	C71.0	Cerebral [JC - RAD]
+	C71.0	Internal capsule
+	C71.0	Basal ganglia
+	C71.9	Craniotomy (Heuristic, JC - RAD)
+	C76.0	Head
+	C76.4	Hand, NOS
+	C76.5	Leg, NOS
+	C80.9	Fluid
+	COVER	lateral mass
+	HX	History
+	M-80001	Mass, NOS [JC - RAD]

Case Finding

- Positive
- Positive - Previously Known
- History
- Metastatic
- Negative
- Flag report

Manual: **Auto:** Possibly New

Comment

'' (+)C30.1 (+)C41.0 (+)C71.0 (+)C71.9 (+)C76.0 (+)C76.4 (+)C76.5 (+)C80.9 (+)COVER (+)M-80001

[NATURE OF SPECIMEN]

CT HEAD WITHOUT CONTRAST

Technique: Sequential 5 mm axial images.

[GROSS PATHOLOGY]

Findings:
Again demonstrated is age-appropriate generalized cerebral volume loss. Moderate white matter disease is again seen, likely representing chronic microangiopathy, and essentially unchanged. Focal hypodensity again noted, in the anterior limb of the right internal capsule, consistent with remote lacunar infarction. Slightly asymmetric basal ganglia mineralization again noted, more prominent on the left. Attenuation of cortex and white matter is otherwise normal. There are no findings to suggest acute, large vascular distribution cortical infarction. There is no hemorrhage or abnormal extra-axial fluid collection.
Degenerative changes are noted, at the occipito-atlantal articulation. There is asymmetry of the space between the dens and lateral mass of, however, appearance is unchanged. Skull base and calvarium appear intact. Mastoid air cells, middle ear cavities and included paranasal sinuses are essentially clear. Soft tissue **mass** noted, in left nares, likely representing a polyp. Appearance is unchanged.

[CLINICAL HISTORY]

falls, r/o bleed or stroke.

Indication: 99-year-old female, status post fall. Patient complains of right hand tingling and bilateral leg weakness. CT has been requested to exclude stroke or hemorrhage.

[FINAL DIAGNOSIS]

IMPRESSION:
Chronic changes are demonstrated, essentially unaltered when compared to previous study 4/18/2007. There is no evidence of superimposed acute intracranial pathology.
Job: 493401

What about sites beyond CNS?

- Attempted to process Pancreas and biliary reports.
- Not specific enough to isolate only to these organs
- Would have produced lots of reports that were already in registry, eg: liver biopsy, etc..

Tried to include Biliary, Pancreas reports – problem!

Report Classifier - C:\DEV\Radiology\Phase II\Pancrease - Billary data\Positive

File Edit Tools

Report	Auto CF	CF
20100804-115359	0	
20100615-145037	0	
20100803-154441	0	
20100803-160146	3	
20100803-173027	0	
20100803-174245	0	
20100804-110918	1	
20100804-111003	1	
20100804-111015	1	
20100804-111043	0	
20100804-111126	0	
20100804-111325	0	
20100804-111435	1	
20100804-111645	1	
20100804-111654	1	
20100804-111720	0	
20100804-111726	0	
20100804-111821	1	
20100804-112100	1	
20100804-112123	1	
20100804-112123	1	
20100804-112125	1	
20100804-112138	0	
20100804-112210	1	
20100804-112341	1	
20100804-112436	0	
20100804-112511	0	
20100804-112527	0	
20100804-112532	1	
20100804-112553	1	
20100804-112553	0	
20100804-112557	1	
20100804-112610	1	
20100804-112649	0	
20100804-112700	0	
20100804-112920	1	

	Code	Description
-	AIM-930-011	recurrence
-	AIM-930-022	infiltration
-	AIM-930-999	fat infiltration
+	C06.9	oral [AJ - RAD]
+	C18.9	Colon, NOS
+	C19.9	Colectomy
+	C22.0	Liver
+	C23.9	Gallbladder
+	C25.9	Pancreas, NOS
+	C26.0	Bowel, NOS
+	C34.9	Lung, NOS
+	C38.0	Pericardium
+	C38.0	Heart
+	C41.2	Spine
+	C42.2	Spleen
+	C49.4	Abdominal aorta
+	C64.9	Renal, NOS
+	C67.9	Urinary bladder, NOS
+	C74.9	Adrenal gland, NOS
+	C76.2	Abdomen, NOS
+	C76.3	Pelvis, NOS
+	C80.9	Fluid
+	HX	hx [AJ - RAD]
-	M-80001	Mass, NOS [JC - RAD]
+	M-80003	Cancer
-	M-80006	Metastatic
+	M-80103	Carcinoma, NOS
+	M-81400	Adenoma, NOS

Case Finding

○ Possibly New ○ Positive ○ History/Metastatic

○ Negative ☐ Flag report

Comment

History of/Metastatic

[COMMENT]

RADIOLOGY REPORT

[NATURE OF SPECIMEN]

CT ABD W/CONT; CT PELVIS W/CONT
M10CT06040079
CT scan of the abdomen and pelvis with contrast.
Helical CT of the abdomen and pelvis was performed following the administration of oral contrast and during an uneventful injection of 100 cc of Optiray 320 low osmolar nonionic contrast media.
ABDOMEN: Minimal atelectatic changes are present within the lung bases, but there are no infiltrates, nodules, or pleural effusions. The heart and pericardium are within normal limits.
The liver is of diffusely decreased attenuation, suggesting fatty infiltration. Granulomatous calcifications are observed within the liver and spleen. There are surgical clips in the gallbladder fossa. In addition, postoperative changes consistent with a near complete colectomy are again identified.
No retrocrural, retroperitoneal, or mesenteric lymphadenopathy is observed. Multiple renal cysts are seen bilaterally. The left adrenal gland demonstrates heterogeneous lobulated prominence which is a stable finding. The right adrenal gland and pancreas are unremarkable.
Atherosclerotic calcifications are noted within the abdominal aorta, but there is no aneurysmal dilatation. Degenerative changes can be seen throughout the lumbar spine.
PELVIS: No pelvic **masses**, free fluid, or lymphadenopathy are observed. Calcified phleboliths are seen on the left. The urinary bladder and visualized loops of bowel are within normal limits.

[CLINICAL HISTORY]

COLON CA
ADMIT DATE/TIME: SERVICE DATE/TIME: 06/04/10 1330
21 January 2010, 22 June 2009, and 5 May 2009.
CLINICAL HISTORY: Abdominal pain. History of colon cancer diagnosed about one year ago.

[FINAL DIAGNOSIS]

1. Stable postoperative changes, with no evidence of recurrent or metastatic disease.
2. No interval change in the appearance of the lobulated enlargement of the left adrenal gland. Lack of change suggests this probably represents diffuse hyperplasia or perhaps multiple adenomas.
Dictated by: Andrew L Laurel, M.D.
Images and Report reviewed and interpreted by: Andrew L Laurel, M.D.
<PS><Electronically signed by: Andrew L Laurel, M.D.>
06/04/2010 1709
D: 06/04/2010 1704
T:
<CL>
06/04/10 1710

Production system

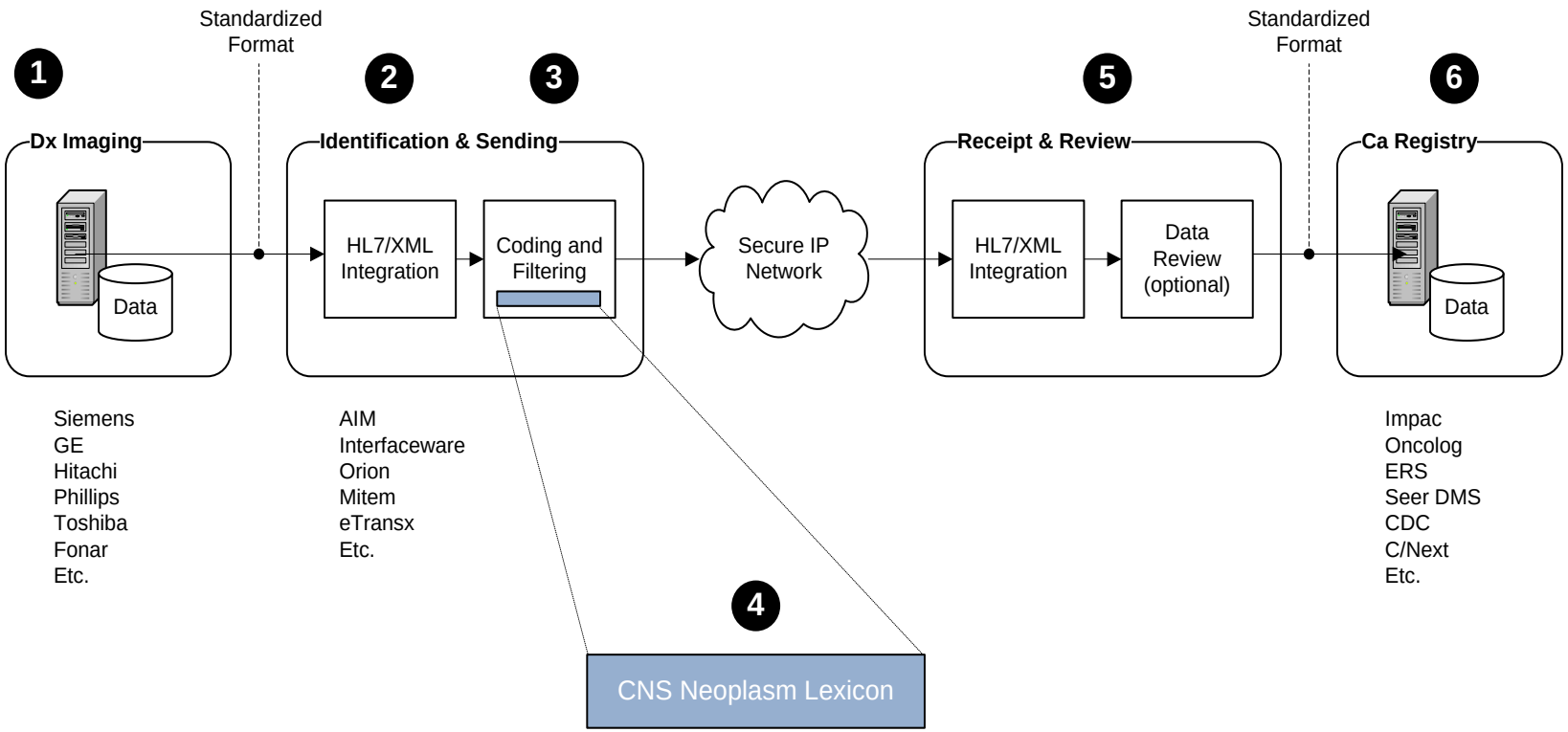

Conclusion

- System implemented at three pilot sites
- QC studies will commence to determine Sensitivity/Specificity for selectable reports
- Determine accuracy in supplementary classifications
- System can be used as E-path add-on, or as standalone